

## Maintenance of oral function in 3 cats with dental resorption

Anna S. Spirina<sup>1</sup>, David A. Crossley

<sup>1</sup>Veterinary clinic “Dentalvet”, Moscow, Russia

Received November 1, 2019

Accepted February 25, 2020

### Abstract

Mandibular molar tooth function is important for cats, however, current veterinary dental practice is to extract teeth affected by even very small resorptive lesions. The aim of this article was to describe an attempt at salvaging mandibular molar teeth where the mesial root and associated crown remained unaffected by resorption. Three cats presented with localised resorption of the distal root of a mandibular molar tooth were treated by hemisection, extraction of the distal root and endodontic treatment of the mesial root. The oral function was maintained in all three cats with no clinical evidence of pain or further resorption at follow-up 10 months post treatment. One cat was also examined at 27 months post treatment, at which stage there was still no oral discomfort and the tooth appeared fine but there were radiographic signs suggestive of early apical resorption. Whilst longer term follow-up is required, it appears that hemisection may be an acceptable treatment for these localised resorptive lesions, at least for the short to medium term.

*Feline, tooth resorption, hemisection, endodontic therapy*

Thorough clinical examination of the feline oral cavity frequently reveals a variety of pathology, often including painful resorptive lesions (Marretta 2000). As orally exposed dental resorption is typically both painful and progressive, it has become general practice for veterinary dentists to treat affected teeth by extraction (DuPont and DeBowes 2009; Reiter 2012). This raises a challenging ethical issue. Is it appropriate to deprive an animal of the ability to chew when it may be possible to maintain pain-free function using alternative treatment methods?

It has been shown that simple restoration of orally exposed dental resorptive lesions is not effective in cats as the restorations are generally lost within a short period due to ongoing resorption which also results in the return of pain (Lyon 1992; Niemiec 2012). Successful endodontic treatment of traumatised feline teeth (particularly canines and carnassials) has been described by several authors (Gorrel and Robinson 1995; Niemiec 2011), and hemisection is commonly practiced in dogs to maintain function of important chewing teeth (Reiter et al 2005). So, could hemisection be applied in cats where only one root of a multi-rooted tooth is affected by resorption? For example, when the small distal root of the mandibular molar teeth is resorbing but the mesial root and crown are unaffected. In such a situation it should be possible to remove the entire resorptive lesion whilst maintaining the more functional, mesial, portion of the tooth. Even if resorption developed in the remaining tooth structure there would be no dental pain as conventional root canal treatment removes the associated nerves.

The aim of this report was to describe the treatment of three cats that had localised external resorption of the distal root of the mandibular first molar tooth by hemisection with extraction of the affected distal root, endodontic treatment of the mesial root and restoration of the crown, with the intention to maintain pain-free oral function.

---

#### Address for correspondence:

Dr. Anna S. Spirina, PhD  
Veterinary clinic “Dentalvet”  
109431 Russia, Moscow  
Street Aviakonstruktora Mile 2/1

Email: [twinsdvm@gmail.com](mailto:twinsdvm@gmail.com)  
+79104597732  
<http://actavet.vfu.cz/>

## Clinical cases

### Case 1

A 4-year-old intact male Maine Coon cat was presented for oral examination as the owners had noticed increasing oral discomfort over the last 4 months. Tooth brushing was previously performed at home 3 times a week but had become irregular as it was no-longer tolerated by the cat due to the oral discomfort. The reduced frequency of tooth brushing had resulted in a noticeable increase in gingivitis. On oral examination, all of the cat's incisor teeth were missing. Slight calculus and gingivitis were observed affecting most of the remaining teeth, and there was a small defect at the gingival margin of the right mandibular molar tooth (409) (Plate IX, Fig. 1A). The rest of the physical examination was unremarkable.

Based on the level of oral inflammation and the abnormality affecting the molar tooth, general anaesthesia was planned to permit a more thorough examination, including probing, charting and intraoral radiography, prior to the required oral hygiene procedure (dental scaling and polishing) and any other necessary treatment. The owner requested maintenance of the molar tooth if possible, even if there was a resorptive lesion as suggested by the visible defect, so it was agreed that an attempt would be made to salvage the tooth by performing hemisection rather than extraction, providing that there appeared to be a good chance of the result being pain-free and functional.

Preoperative workup was within normal limits. So, oral examination and radiography was performed under general anaesthesia. The investigations confirmed the presence of a localised resorption (type 1, stage 2 – see Table 1) at the cemento-enamel junction of the distal root and crown of the right mandibular molar tooth (409) (Plate IX, Fig. 1B). Following oral hygiene, this tooth was treated as planned (Plate IX, Fig. 1C).

Table 1. Classification of external tooth resorption (TR) based on the American Veterinary Dental College nomenclature ([avdc.org/Nomenclature/Nomen-Teeth.html#resorption](http://avdc.org/Nomenclature/Nomen-Teeth.html#resorption)).

Types of TR based on radiographic appearance		
Type 1	T1	Focal or multi-focal radiolucency affecting a tooth with otherwise normal radiopacity and normal periodontal ligament space.
Type 2	T2	Narrowing or disappearance of the periodontal ligament space in at least some areas and decreased radiopacity of part of the tooth.
Type 3	T3	Both type 1 and type 2 are present in different parts of the same tooth.
Extent of TR based on physical examination and radiographic appearance		
Stage 1	TR1	Minimal dental hard tissue loss (cementum or cementum and enamel).
Stage 2	TR2	Moderate dental hard tissue loss (extension into dentine that does not involve the pulp cavity).
Stage 3	TR3	Deep dental hard tissue loss involving the pulp cavity whilst the tooth retains its basic integrity.
Stage 4	TR4	Extensive dental hard tissue loss leading to loss of tooth integrity.
	TR4a	Crown and root are equally affected.
	TR4b	Crown is more severely affected than the root.
	TR4c	Root is more severely affected than the crown.
Stage 5	TR5	The crown of the tooth is absent with gingiva covering its site. Remnants of dental hard tissue can be detected as irregular radiopacities.
<i>There is no classification for totally resorbed teeth with no remnants of dental hard tissue.</i>		
<i>Author's comment</i>	<i>This stage can only be identified in cases where there is a known history of previous untreated resorption.</i>	

## Case 2

A 6-year-old intact female Domestic shorthair cat was presented for a routine oral examination. The owner had not noticed any oral problem, however, on examination there was halitosis with significant calculus buildup, being particularly marked on the maxillary fourth premolars (108 and 208) (Plate X, Fig. 2). The majority of the incisor teeth were missing. Gingivitis was present affecting all the remaining teeth to some degree, with gingival overgrowth around the right mandibular third premolar. The physical examination was otherwise unremarkable. Preoperative workup was within normal limits so the cat was admitted for further examination, oral hygiene and any other necessary dental treatment.

Following induction of anaesthesia, a detailed oral examination was performed. This confirmed the previous findings and identified 2 teeth with suspected resorptive lesions. Radiographic examination confirmed that the right mandibular molar tooth (409) was affected lingually by a type 1, stage 2 resorption on the distal aspect of the crown and that the mandibular third premolar (407) was affected by type 3, stage 3 resorption (Plate XI, Fig. 2A). Following oral hygiene measures, the resorbing premolar tooth was treated by crown amputation as both roots were affected, leaving the already resorbing roots buried beneath a gingival flap (DuPont 1995; DuPont 2002), whilst hemisection and endodontic therapy were performed on the molar tooth (Plate XI, Fig. 2B).

## Case 3

A 3-year-old intact male Angora cat was presented with an 8-month history of oral discomfort. Tooth brushing was performed at home intermittently, but with difficulty. Slight calculus and marginal gingivitis were present throughout the oral cavity. The rest of the physical examination was unremarkable and preoperative workup was again within normal limits so the cat was admitted for treatment.

Following induction of anaesthesia, it became evident that there was more prominent gingivitis caudal to the left mandibular molar tooth (309) (Plate XII, Fig. 3). Radiographic examination confirmed the presence of a type 1, stage 2 resorption at this location (Plate XII, Fig. 3A). After oral hygiene work was completed, hemisection of tooth 309 was performed with endodontic treatment of the remaining healthy root (Plate XII, Fig. 3B).

## Treatment outline

### Anaesthesia

All three cats were anaesthetized according to the same protocol. They were premedicated with promethazine (Pipolphen, EGIS, Hungary) (1 mg/kg i.m.), atropine sulphate (Atropine, Belmedpreparaty, Republic of Belarus) (20 mg/kg s.c.), plus diazepam (Diazepam Relanium, POLFA, Warsaw Poland) (2 mg/kg i.m.). Once this had taken effect, general anaesthesia was induced using ketamine hydrochloride (Ketamin, Moscow Endocrine Plant, Moscow) (3 mg/kg i.m.) and medetomidine (Meditin, Api-san, Russia) (0.04 mg/kg i.m.). This was followed by endotracheal intubation to permit anaesthetic maintenance by inhalation using 0.5–1% isoflurane (Foran, Abbott Laboratories, United Kingdom) in oxygen (1 l/min). Ringer's solution was infused at a flow rate of 25 ml/h through a 22-gauge intravenous catheter from induction to recovery. Patient parameters were monitored using reflex assessment, auscultation and electrocardiography and body temperature was maintained using heating pads and blankets. Additional pain control was achieved by performing mandibular nerve blocks using articaine (Ultracaine, Sanofi-Aventis, France) (2.0 mg/kg).

### Tooth hemisection

Ultrasonic scaling and polishing of the teeth was performed and the oral cavity was disinfected with a 0.05% solution of chlorhexidine bigluconate (Chlorhexidine 0.05%,

Rosbio, Russia). Following radiographic identification of a resorptive lesion that appeared amenable to treatment (Plate XIII, Fig. 4A), the gingiva was reflected, creating a shallow envelope flap around the affected area, deep enough to prevent gingival damage during tooth sectioning and root extraction. Hemisection was performed using a FG699 carbide cutting bur in a high speed dental handpiece with water cooling. The cut was started at the furcation, cutting coronally to remove a section of the distal cusp of the tooth and all detectable resorbing tooth structure. The distal root was then extracted using a thin tipped dental luxator and the root extraction site was sutured closed with 5-0 PGA (PGA, Volot, Russia). Sharp edges on the remaining portion of the tooth were carefully smoothed using a flame diamond bur. Access was gained to the pulp chamber over the mesial root with a round diamond bur 010 and a standard root canal treatment performed using radiographic control (Plate XIII, Fig. 4B) (Gorrel and Robinson 1995). Working length was established using a pathfinder file and the canals prepared and shaped using a combination of K and Hedstrom files (sizes 15–20), with frequent flushing with 3% NaOH solution. Once prepared, the canals were flushed for 60 s with NaOH solution, then sterile water for further 20 s and dried with sterile paper points. Calcium hydroxide based root canal sealer (Sealapex, Kerr Corporation, Orange, California, USA) was placed in the prepared root canals using lentulo spiral fillers using a speed reducing handpiece prior to placement and plugging of a gutta percha point. The access site and exposed pulp chamber were then restored using dental light curing composite (Vertise™ Flow, Kerr Italy) and the treated tooth radiographed (Plate XIII, Fig. 4C). At the end of the procedure the oral cavity was again flushed with dilute chlorhexidine solution and a dental adhesive paste containing benzyldimethyl and solcoseryl (Solcoseryl adhesive dental paste, Legacy, Switzerland) was applied over the sutured gingiva to protect the extraction site.

#### Postoperative care

Postoperative analgesia was provided using tramadol (Tramal, Polfarma, Russia) (2 mg/kg i.m., 3 day) and meloxicam (Meloxidil, Ceva Sante Animale, France) (0.1 mg/kg p.o., 5 days). The owner was supplied with the protective paste to be applied locally daily for 7 days, if possible, to provide ongoing physical protection of the extraction site. Soft food was advised for the first 3 days, at which stage it was advised to restart daily tooth brushing using a soft bristled toothbrush and pet toothpaste.

#### Follow-up

All 3 cats were presented after 2 weeks for postoperative examination. The owners all reported that their cats were doing well, eating normally with no indications of pain, and that tooth brushing was being performed. At this examination the mucosa and gingiva appeared healthy with no signs of inflammation and the gingiva at the extraction sites had healed well.

Ten months after the procedure, scaling and polishing were again required for all three cats as the owners had not been able to maintain a thorough daily oral homecare regime (as is frequently the case in cats). Probing and radiographic examination of the hemisection sites while the cats were under anaesthesia for the oral hygiene procedure did not reveal any pathological findings and the endodontically treated tooth roots remained structurally sound and showed no periapical pathology (Plate XIV, Fig. 5AB).

In Case 1, radiographic monitoring was performed again at a further routine scaling and polishing procedure 27 months after the hemisection. The treated tooth had remained functional with no signs of oral pain and only a very mild marginal gingivitis similar to that affecting the adjacent teeth (Plate X, Fig. 6A). The radiograph confirmed that the tooth remained substantially intact, however, there was a coarse trabecular pattern overlying the root apex. This suggested that there was localised apical resorption present (Plate X, Fig. 6B) so further follow-up was advised.

## Discussion

Tooth resorption may originate internally, starting within the root canal/pulp cavity, or externally, starting on the outer surface of the tooth, usually the root surface. External resorption is classified based on its pattern (types 1–3) and the severity of the resorption (stages 1–5), according to AVDC classification of external tooth resorption (Table 1).

External tooth resorption is common in domestic cats, with reported prevalence rates ranging within 28.5–67.0% (Coles 1990; Verstraete et al. 1996; Patel et al 2010). The incidence of dental resorptive lesions increases with age. Cases frequently present clinically with a hard tissue defect at the cemento-enamel junction of the tooth. Any tooth may be affected, but lesions are detected more frequently in the smaller premolars and canine teeth (Coles 1990).

Supragingival resorptive lesions expose sensitive dentine to the oral environment inducing pain, but signs are often subtle and masked by many cats. This factor and the limited visibility within the oral cavity can make resorption difficult to detect in a conscious cat. Whilst the commonly described manifestation of a defect at the cemento-enamel junction can sometimes be diagnosed clinically by visual and tactile examination, studies have demonstrated that external resorption can occur anywhere on the root surface, i.e., not only at the cemento-enamel junction (Coles 1990; Gorrel 2014). As completely embedded lesions do not appear to be painful, there is usually no external indicator of their presence, so, radiographic examination is required for accurate diagnosis. This also applies to coronal lesions hidden by local gingival enlargement, as seen in Case 2, affecting the premolar tooth.

As suggested above, routine radiography is required for timely diagnosis and assessment of dental resorptive lesions, clinical (visual and tactile) methods only detecting a small proportion of lesions. Even high definition dental radiography is not 100% reliable as only lesions within its resolution are detected, the earliest microscopic lesions remaining undetected. The proportion of such microscopic lesions that progress to clinical significance is unknown. When lesions are detected, tooth extraction is currently considered the gold standard treatment with coronal amputation being accepted for advanced type 2 and 3 lesions (DuPont 1995; DuPont 2002).

The stated aim of modern veterinary dentistry is the maintenance of comfortable oral function (WSAVA Global Dental Guidelines). This is not met by the extraction of functional teeth that could be maintained in a pain-free manner. Unnecessary extraction of teeth is maybe in effect a mutilation (similar to tail docking, ear cropping and declawing) that reduces oral function. Even though domestic pets usually adapt to tooth loss, extraction can only be justified when the tooth is dysfunctional or causing pain and cannot be treated appropriately. Loss of incisors and small premolars has minimal effect on chewing, whereas, loss of carnassial teeth prevents normal chewing. The above concerns, and the preference of many owners to maintain their pets' dentition, prompted the authors to seek methods of salvaging structurally sound chewing teeth that would normally be extracted, in particular cats' mandibular molars. The anatomy of these teeth is such that the mesial root and cusp remain strong and functional when the distal root and cusp are lost.

Hemisection is a viable alternative to extraction in those situations where a portion of a multi-rooted tooth has normal root canal structure and can still perform in health and function after the diseased portion has been removed (Swan et al 1991). As described earlier, the procedure involves removing the compromised tooth structure (root and part of the crown). After appropriate preparation, a root filling is then placed in the residual root and the crown sealed. The process of root canal treatment removes the dental nerves, preserves a functional tooth segment and thus maintains chewing physiology (Swan et al 1991). Even if a treated tooth goes on to develop further resorption, the lack of

nerves prevents recurrence of tooth pain permitting retention of the tooth until it becomes structurally unsound.

As demonstrated by the described cases, hemisection appears to be an acceptable alternative to extraction in appropriately selected cases and could be applied to maxillary carnassial and even the smaller premolar teeth, however, the very small size of the latter creates technical difficulties in performing root canal treatment.

The choice of root filling materials and for the endodontic procedure is important. Biocompatible root canal sealer and root filling materials are required. In view of the possible later resorption of treated tooth roots it may be preferable to entirely fill the root canal with calcium hydroxide based sealer as this is resorbable, unlike gutta percha which, although biologically inert (Kaur et al. 2015; Kazeko et al. 2015), would remain to become a foreign body.

## Conclusion

From the results of the three described cases, it appears that hemisection with endodontic treatment of the mesial root is a suitable alternative to extraction of some partially resorbed mandibular molar, and possibly other multi-rooted teeth in cats, however, it would be wise for a larger series of cases to be monitored over a longer period before this becomes a general recommendation.

## References

- Coles S 1990: The prevalence of buccal cervical root resorptions in Australian cats. *J Vet Dent* 7: 14-16
- DuPont G 1995: Crown amputation with intentional root retention for advanced feline resorptive lesions - a clinical study. *J Vet Dent* 1: 9-13
- DuPont G 2002: Crown amputation with intentional root retention for dental resorptive lesions in cats. *J Vet Dent* 19: 107-110
- DuPont G, DeBowes L 2009: Atlas of Dental Radiography in Dogs and Cats. First Edition, Saunders, 288 p.
- Gorrel C 2014: Tooth resorption in cats. Pathophysiology and treatment options. *J Feline Med Surg* 17: 37-43
- Gorrel C and Robinson J 1995: Endodontics in small carnivores. In: Crossley DA and Penman S. (Eds), Manual of Small Animal Dentistry. 2. British Small Animal Veterinary Association, United Kingdom, pp. 168-181
- Kaur A, Shah N, Logani A, Mishra N 2015: Biototoxicity of commonly used root canal sealers: A meta-analysis, *J Conserv Dent* 18: 83-88
- Kazeko LA, Karmalkova IS, Kolb EL 2015: Obturation techniques of root canal system. Minsk BSMU
- Lyon KF 1992: Subgingival odontoclastic resorptive lesions. Classification, treatment, and results in 58 cats. *Vet Clin North Am Small Anim Pract* 22: 1417-1432
- Marretta SM 2000: Dentistry and diseases of the oropharynx. In: Birchard SJ, Sherding RG (Eds): Saunders Manual of Small Animal Practice. Second edition, Philadelphia: W.B. Saunders, pp. 702-725
- Niemiec BA 2011: Veterinary Endodontics; In: <https://todaysveterinarypractice.com/practical-dentistry-proper-therapy-for-endodontic-disease/>
- Niemiec BA 2012: Today's Veterinary Practice; In: <https://todaysveterinarypractice.com/dental-services-good-medicine-for-patients-practices/>
- Patel S, Ricucci D, Durak C, Tay F 2010: Internal root resorption: a review. *J Endod* 36: 1107-21
- Reiter AM 2012: Dental and Oral Diseases. In: Little S (Ed.): The Cat: Clinical Medicine and Management, Elsevier, Saunders, pp. 329-370
- Reiter AM, Lewis JR, Rawlinson JE, Gracis M 2005: Hemisection and partial retention of carnassial teeth in client-owned dogs. *J Vet Dent* 22: 216-226
- Swan RH, Rapley JW, Schindler WG, Mathey WS 1991: Hemisection of a molar tooth in a dog: an alternative to total extraction. *J Vet Dent* 8: 12-13
- Verstraete FJM, van Aarde RJ, Nieuwoudt BA, Mauer E, Kass PH 1996: The dental pathology of feral cats on Marion Island. Part II: periodontitis, external odontoclastic resorptive lesions and mandibular thickening. *J Comp Pathol* 115: 283-297
- World Small Animal Veterinary Association Global Dental Guidelines. WSAVA Web site. Available at: <https://www.wsava.org/Global-Guidelines/Global-Dental-Guidelines>

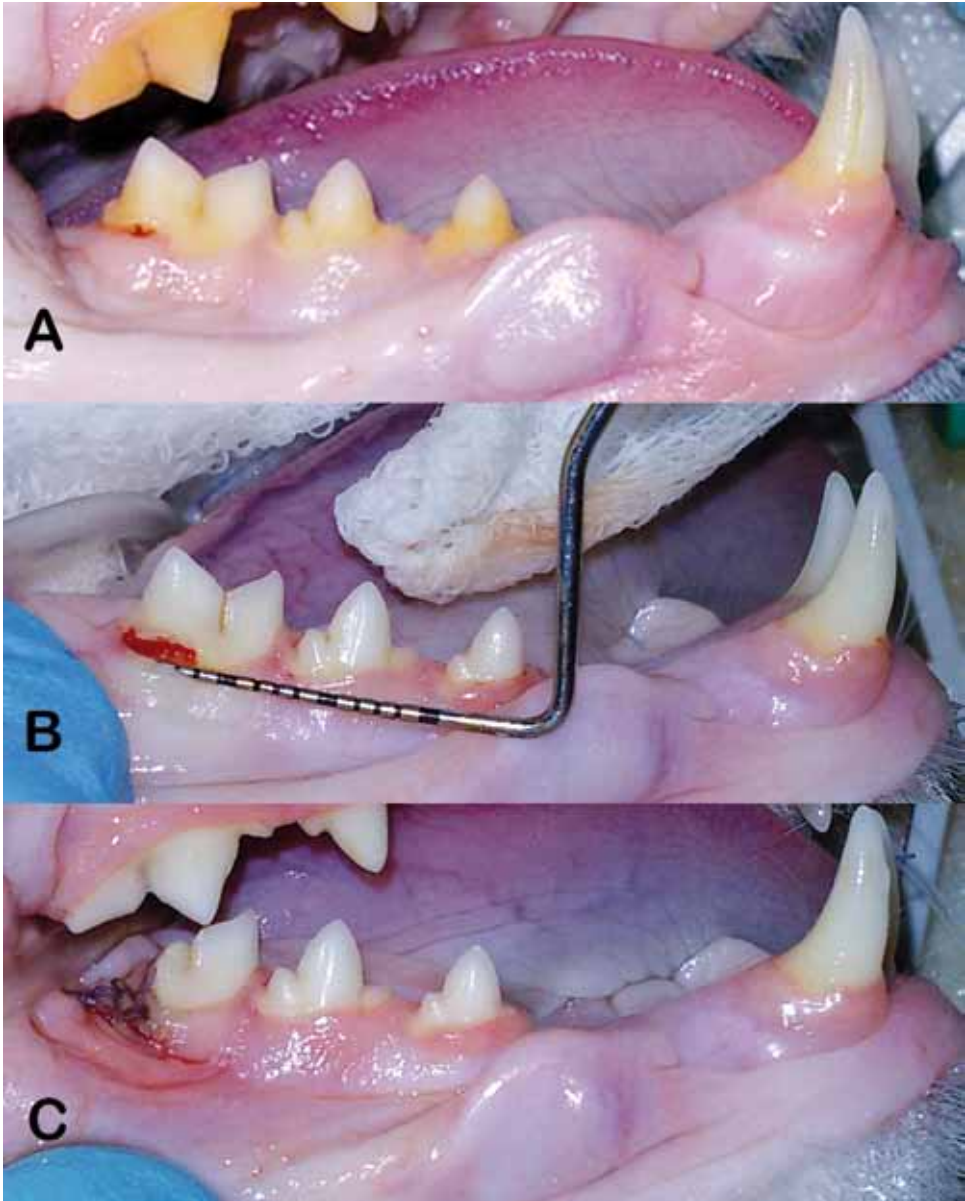


Fig. 1. Case 1: (A) Pre-operatively, plaque deposits can be seen on the teeth with associated gingivitis. There is slight gingival recession exposing a small resorptive lesion affecting the distal root of the mandibular molar tooth (409). (B) The resorptive lesion is seen to be significantly larger following dental scaling and gingival reflection. (C) The appearance of the molar tooth following treatment by hemisection. The site of the distal root extraction has been closed with a gingival flap.

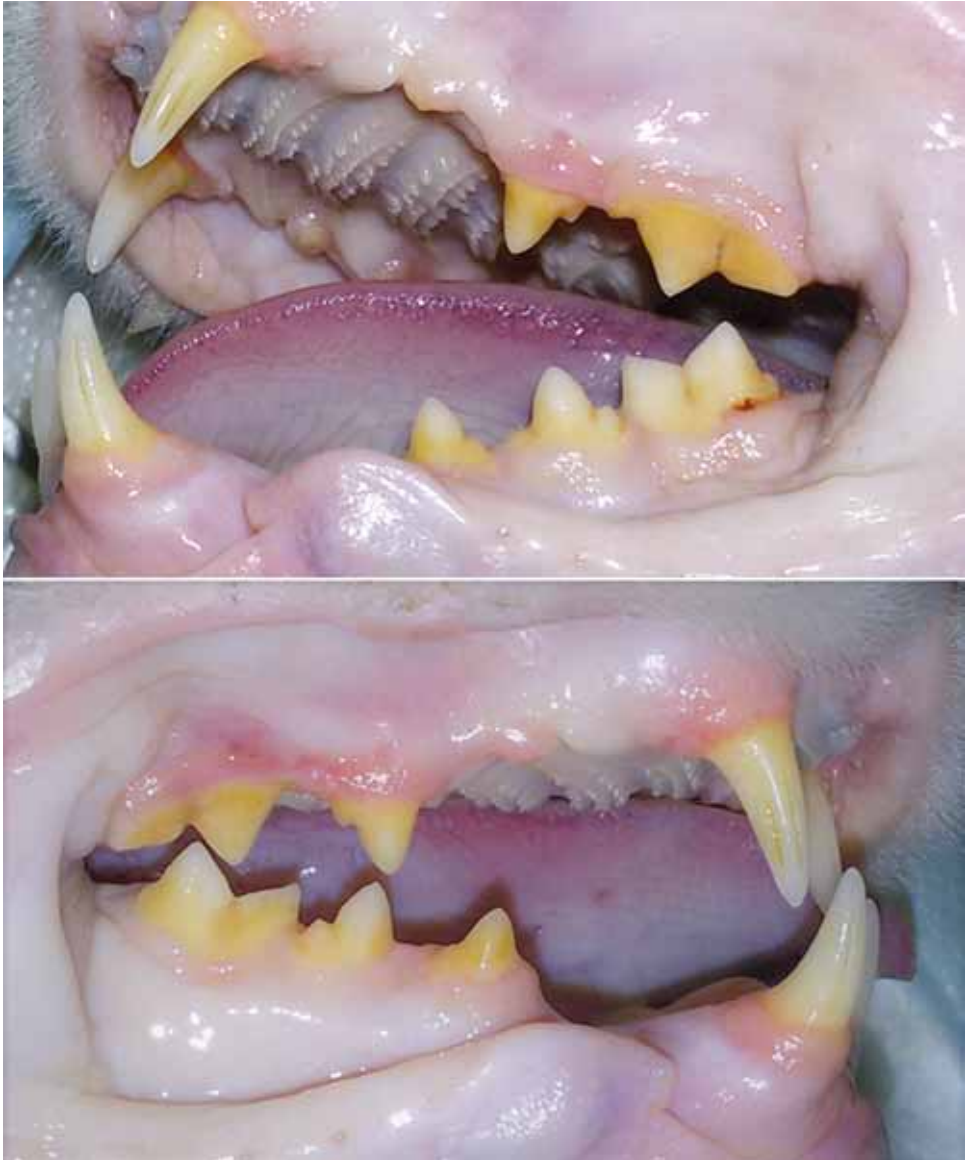

Fig. 2. Case 2: There are significant plaque deposits on all visible teeth with associated gingivitis. There is calculus on the maxillary fourth premolar tooth (108). There is some gingival overgrowth around the mandibular 3<sup>rd</sup> premolar (407). There is no visible evidence of resorptive lesions.



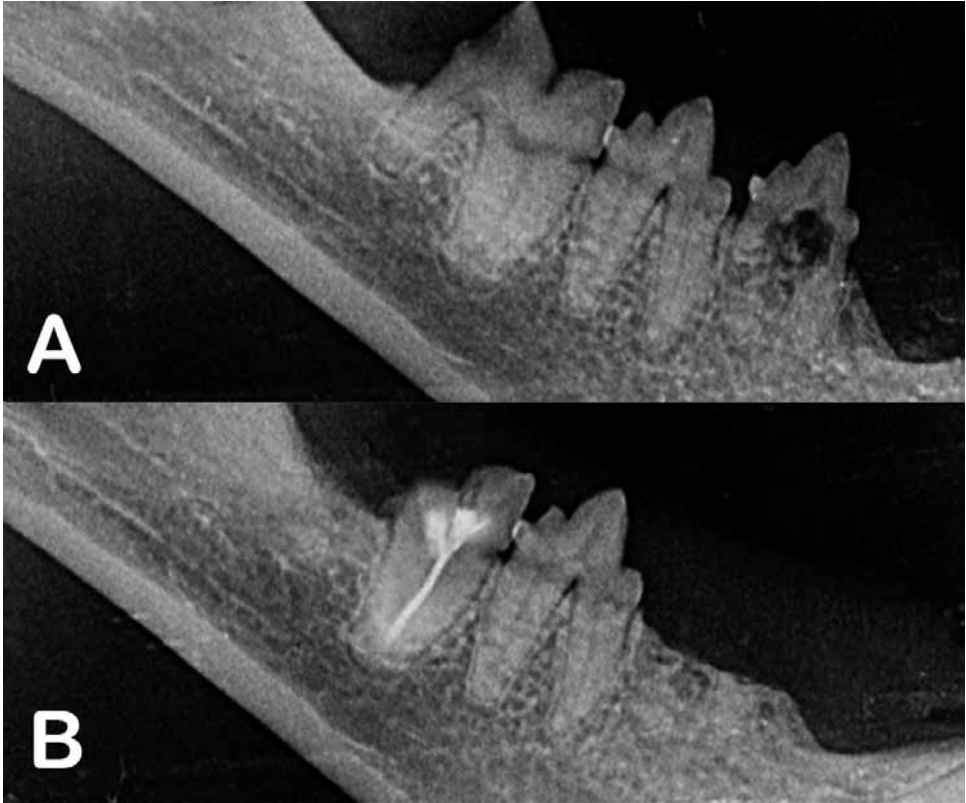


Fig. 2AB: Intraoral radiographs from case 2: (A) Preoperative image showing the coronal defect affecting the molar tooth (409) and combined root and crown resorption affecting the third premolar tooth (407). (B) Post treatment image showing the endodontically treated mesial root of the molar tooth (409) and the crown amputation of the premolar (407).

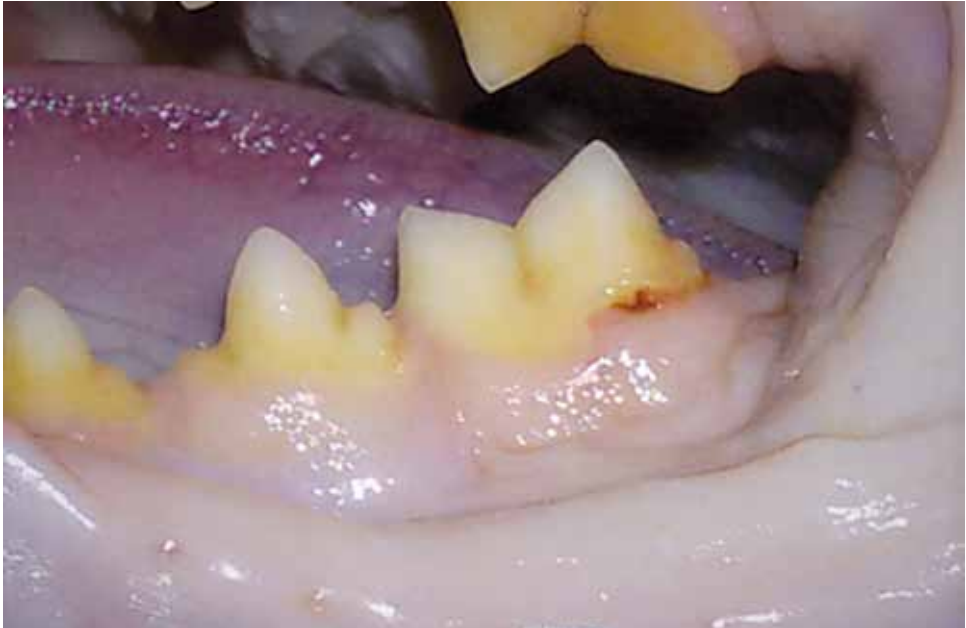

Fig. 3. Case 3: There are significant plaque deposits on all visible teeth with associated gingivitis. There is a resorptive lesion affecting the distal root of the mandibular molar tooth (309)

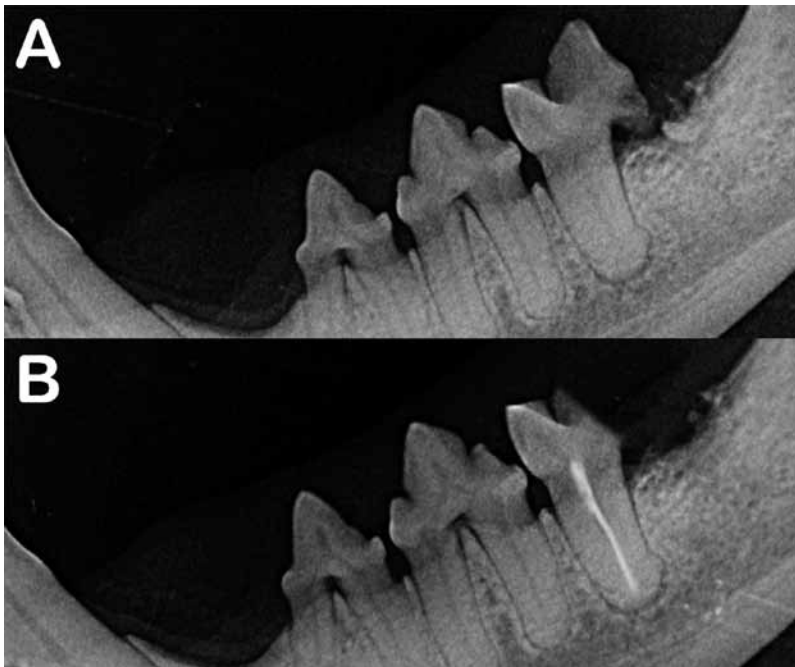


Fig. 3AB: Intraoral radiographs of case 3: (A) Preoperative image showing resorption of the distal root of the molar tooth (309). (B) Post-treatment image showing the endodontically treated mesial root of the molar tooth (309).

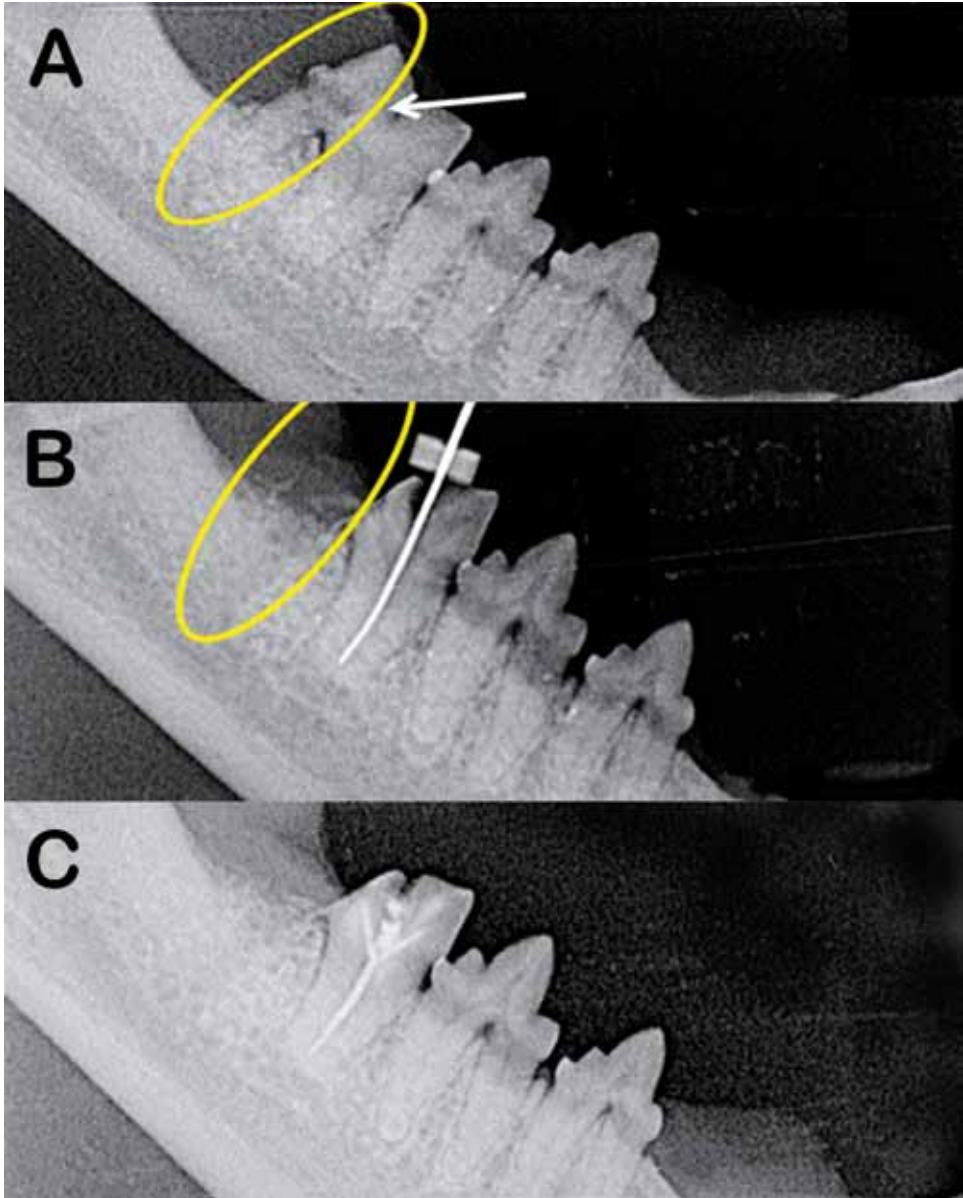


Fig. 4: Intraoral radiographs of case 1: (A) The arrow indicates the depth of resorption into the mandibular molar tooth (409). (B) During endodontic treatment of the mesial root of the molar tooth following hemisection and distal root extraction to remove the resorption affected tooth segment. (C) The remaining mesial root of the molar tooth at the end of the procedure.

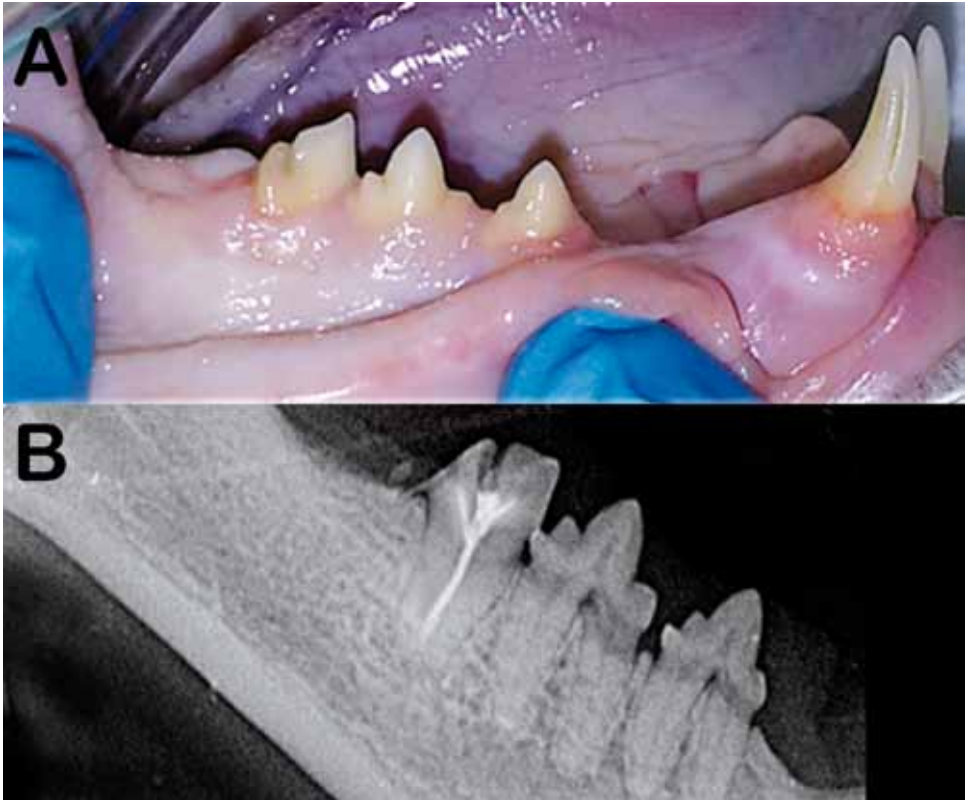


Fig. 5. Case 1 at 10 months following hemisection: (A) Oral photograph showing the treated mandibular molar tooth (409). (B) Radiograph showing the endodontically treated tooth root with no pathology or other complications.

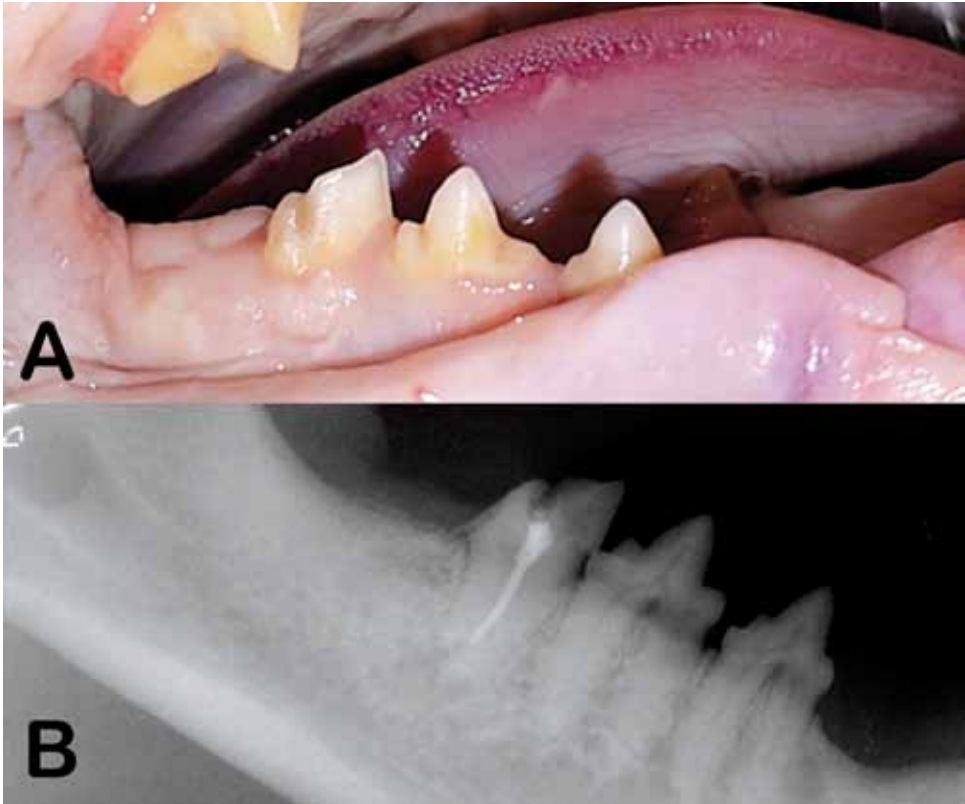

Fig. 6. Case 1 at 27 months following hemisection: (A) Oral photograph showing the still functional mandibular first molar tooth (409) surrounded by clinically healthy gingiva. (B) Intraoral radiograph showing that the treated tooth remains structurally sound. However, there are two areas of radiolucency overlying the root apex that are likely to be due to resorption rather than a coarse trabecular bone pattern, so further follow-up was advised.