

Treatment of Monteggia fractures in cats with external fixation

Kerem Yener^a, Ali Hayat^b, Ünal Yavuz^c, Kübra Dikmen İlginoğlu^d,
Mehmet Salih Karadağ^e, Mehmet Sıdık Hurma^f

Harran University, Faculty of Veterinary Medicine, Department of Surgery, Şanlıurfa, Türkiye

ORCID: ^a0000-0002-6947-0356; ^b0000-0002-8597-0705; ^c0000-0002-4981-2355; ^d0000-0002-6805-1571;
^e0000-0002-4139-913X; ^f0000-0001-7804-6752

Received September 15, 2025

Accepted June 15, 2026

Abstract

Monteggia fractures (MFs) are rare and challenging injuries to treat in cats, characterized by a proximal ulnar fracture with radial head luxation. This retrospective case series aimed to describe the clinical and radiographic outcomes of an epoxy resin-supported Type Ia linear transarticular external fixator (EF) with temporary elbow-spanning configuration used in feline Type I MF cases. Ten cats diagnosed with Type I MF between 2020 and 2024 were included. All fractures resulted from falls from height and were treated using open reduction. Postoperative evaluation included radiographic fracture healing, clinical limb function (lameness score and Campbell test), and complication rates. Data were primarily analysed using descriptive statistics, and interobserver agreement for radiographic assessment was evaluated using the intraclass correlation coefficient (ICC). The mean radiographic healing time was 40.5 ± 5.8 days. Eight cases showed normal healing (< 60 days), while two exhibited delayed union. No cases of malunion, nonunion, or fixation failure were observed. Mild pin tract infections occurred in three cases and resolved with local treatment. Interobserver agreement for radiographic evaluation was high (ICC = 0.91). Acceptable functional outcomes were observed in most cases, including selected cats with intra-articular ulnar involvement. In conclusion, the use of an epoxy resin-supported Type Ia linear transarticular EF with temporary elbow-spanning stabilisation may represent a viable treatment option for selected feline Type I MF cases. However, careful case selection, meticulous surgical technique, and cautious interpretation of outcomes are warranted.

Feline, epoxy resin, radius-ulna, luxation

Monteggia fractures (MFs) are traumatic lesions characterized by fractures in the proximal or middle third of the ulna with luxation of the radial head (Aydın and Yayla 2018; Anatolitou et al. 2024). Monteggia fractures are classified into four main types based on the direction of luxation of the radial head and the angle of the accompanying ulna fracture: Type I: Anterior (cranial) displacement of the radial head with ulna fracture; Type II: Posterior (caudal) displacement of the radial head with ulna fracture; Type III: Fracture in the metaphyseal region of the ulna and lateral dislocation of the radial head; and Type IV: Fracture of the radius and ulna together with luxation of the radial head, which is usually displaced anteriorly (Leclerc et al. 2014; Koch 2017; Anatolitou et al. 2024). In the late 1990s, Type II MFs were divided into four subtypes depending on the localization of the ulnar fracture: Type IIA: the fracture line is located proximal to the olecranon and coronoid process; Type IIB: characterized by diaphyseal ulnar fracture; Type IIC: the fracture line passes distal to the coronoid process; Type IID: fractures occurring in the distal half of the ulna (Boero Baroncelli and Peirone 2009; Anatolitou et al. 2024).

Monteggia fractures are rarely reported in the veterinary literature, with most available data limited to isolated case reports and a small number of retrospective studies (Schwarz and Schrader 1984; Boero Baroncelli and Peirone 2009; Leclerc et al. 2014;

Address for correspondence:

Kerem Yener
Department of Surgery
Faculty of Veterinary Medicine
Harran University, Şanlıurfa, Türkiye

Phone: +90 0506 998 5265
E-mail: keremyener@harran.edu.tr
<https://actavet.vfu.cz/>

Anatolitou et al. 2024). Although MFs have been described in cats, dogs, and non-human primates, the low number of reported cases precludes reliable assessment of species, sex predisposition, or true prevalence. In cats, falls from height are the most commonly reported cause, whereas traffic accidents predominate in dogs (Irubetagoiena et al. 2011; Koch 2017; Schreiber et al. 2022).

Various surgical techniques have been described for the treatment of MFs in small animals, including plate and screw fixation, intramedullary pinning with or without cerclage, transradioulnar positional screws, and annular ligament reconstruction using suture material or synthetic implants (Boero Baroncelli and Peirone 2009; Vallone and Schulz 2011; Schreiber et al. 2022). However, rigid fixation methods and transradioulnar screws may restrict physiological pronation supination movements and often require implant removal, particularly in small or young animals (Irubetagoiena et al. 2011; Jimenez et al. 2021).

In human medicine, external fixator (EF), particularly a temporary elbow-spanning construct, has been widely used as an adjunctive stabilisation technique in complex elbow injuries and MFs to maintain reduction and protect soft tissue repairs while allowing controlled joint alignment (Lu et al. 2013; Wang et al. 2019; Yuan et al. 2020). In veterinary medicine, reports describing the use of external fixation for MFs remain limited and are largely confined to individual cases in dogs and non-human primates (Boero Baroncelli and Peirone 2009; Jimenez et al. 2021).

The aim of the present study was to describe the clinical and radiographic outcomes of a series of feline Type I MFs treated using an epoxy resin-supported Type 1a linear transarticular external fixation construct with temporary elbow-spanning stabilisation.

Materials and Methods

This study protocol was approved by the Local Ethics Committee on Animal Experiments, Harran University (session and permit number: 2025-001/04).

Clinical case details

This retrospective study included 10 cats of different breeds, ages, and sexes diagnosed with MF and admitted to the Harran University Faculty of Veterinary Medicine Animal Hospital between 2020 and 2024. The mean age of the cats was 14.3 ± 3.9 months, and the mean body weight was 4.4 ± 0.6 kg. Six cats were male (60%) and four were female (40%). Seven cats were domestic shorthair (70%), and three were Scottish Fold Blue Point (30%).

Diagnosis was based on clinical examination and orthogonal radiographic evaluation (craniocaudal (Cr/Cd) and mediolateral (M/L) positions). The clinical information evaluated included the cause of trauma, fracture extremity, wound status, and soft tissue damage at the fracture site. All 10 cats included in the study sustained Type I MF, with falls from a height identified as the cause of injury in each case. Fractures involved the right forelimb in six cases (60%) and the left forelimb in four cases (40%). Radiographic assessment of the ulnar fractures identified extra-articular involvement in six cases and intra-articular involvement in four cases. In one cat (Case 6), a Type I MF with intra-articular ulnar involvement of the right forelimb was accompanied by a carpal dislocation of the contralateral forelimb.

Preoperative haematological, biochemical, and blood gas indices were within reference ranges in all cases (Table 1). Although C-reactive protein (CRP) is considered to have limited clinical significance in cats, it was routinely evaluated as part of the preoperative inflammatory assessment protocol used at our clinic. Closed reduction and stabilisation of the carpal joint using cross-pinning were performed during the same anaesthetic episode (Plate IX, Fig. 1). All cases were treated surgically, using open reduction followed by application of an epoxy resin-supported Type 1a linear transarticular EF with temporary elbow-spanning stabilisation (Plate X, Fig. 2).

Fracture repair with linear Type 1a transarticular external fixation

Preoperative clinical evaluation included measurement of body temperature, pulse, and respiratory rate (Mindray UMEC12VET, Mindray, Shenzhen, China). A complete blood count (pocH-100i®, Sysmex, Kobe, Japan), serum biochemistry (Spotchem EZ SP4430, Arkray Inc., Kyoto, Japan), and blood gas analysis (GEM Premier Plus 3000 blood gas analyzer, Instrumentation Laboratory Co., Lexington, MA, USA) were performed to assess systemic status prior to anaesthesia. The evaluated indices included WBC, RBC, MCV, MCH, MCHC, haemoglobin, glucose, creatinine, cholesterol, ALT, AST, bilirubin, albumin, and CRP. Amoxicillin-clavulanic acid (8 mg/kg; Synulox, Haupt Pharma

Table 1. Preoperative haematological, biochemical, and blood gas values of cats with Monteggia fractures.

Indicator	Value (mean \pm SD)
WBC	12.3 \pm 2.1 $\times 10^3/\mu\text{l}$
RBC	8.7 \pm 0.9 $\times 10^6/\mu\text{l}$
Haemoglobin	13.4 \pm 1.2 g/dl
MCV	45.3 \pm 3.4 fl
MCH	14.9 \pm 1.1 pg
MCHC	33.1 \pm 2.3 g/dl
Glucose	104 \pm 17 mg/dl
Creatinine	1.1 \pm 0.2 mg/dl
ALT	47 \pm 8 U/l
AST	39 \pm 6 U/l
Cholesterol	148 \pm 20 mg/dl
Total bilirubin	0.4 \pm 0.1 mg/dl
Albumin	3.4 \pm 0.3 g/dl
CRP	1.7 \pm 0.4 mg/dl
pH	7.38 \pm 0.05
pCO ₂	36.7 \pm 4.2 mmHg
pO ₂	89.4 \pm 8.1 mmHg

WBC: white blood cell count; RBC: red blood cell count; MCV: mean corpuscular volume; MCH: mean corpuscular haemoglobin; MCHC: mean corpuscular haemoglobin concentration; ALT: alanine aminotransferase; AST: aspartate aminotransferase; CRP: C-reactive protein; pCO₂: partial pressure of carbon dioxide; pO₂: partial pressure of oxygen.

percutaneously into the humerus and the radius/ulna using a low-speed drill (≤ 150 r.p.m.). Continuous cold isotonic saline irrigation was applied during pin placement to minimise thermal bone injury. Pins were placed perpendicular to the bone surface, with a minimum inter-pin distance of 1 cm and approximately 1 cm from the fracture line. Epoxy resin was prepared in a 2:1 liquid–liquid ratio and applied within 15-mm-diameter plastic tubes, as previously described by Özak et al. (2009). Continuous saline irrigation was maintained during curing to limit heat generation. Following fixation, the surgical site was irrigated with 0.9% NaCl and diluted povidone–iodine solution (1:10). Muscle, fascia, subcutaneous tissue, and skin were closed routinely using absorbable PGA sutures. The EF was completed by covering the fixator bars with sterile dressings.

Postoperatively, meloxicam (0.03 mg/kg SC; Nobel İlaç, Türkiye) was administered once daily for three days. Amoxicillin–clavulanic acid (12.5 mg/kg p.o., twice daily) was continued for seven days. Restricted activity was recommended, and owners were instructed to perform routine pin-site care using topical antimicrobial spray.

Removal of EF was performed under sedation or general anaesthesia following radiographic and clinical evidence of fracture healing. Pins were cut close to the connecting bars and removed using a low-speed drill to minimise soft tissue trauma. Pin tracts were disinfected with povidone–iodine, and local antimicrobial treatment was continued for five days.

Postoperative radiographic and clinical assessment

Radiographic evaluation was performed every two weeks for 4–6 weeks post surgery in all cases. When radiographic evidence of fracture healing was observed, the EF was removed. All orthogonal radiographs obtained prior to fixator removal demonstrated cortical osseous union, which was subsequently confirmed on follow-up radiographs after fixator removal. Radiographic healing time was recorded for all cases.

Postoperative clinical assessment included evaluation of limb muscle mass (amyotrophy), range of motion assessed using the Campbell test, lameness, functional recovery, recovery time, and development of complications. Lameness was graded using a 5-point scale as previously described by Cook et al. (2010), where 0 = normal, 1 = mild lameness with partial weight bearing, 2 = severe lameness with partial weight bearing, 3 = severe lameness with intermittent weight bearing, and 4 = no weight bearing.

Latina S.r.l., Italy) and meloxicam (0.03 mg/kg SC; Nobel İlaç, Türkiye) were administered subcutaneously as a preoperative. Anaesthesia was induced with intramuscular xylazine HCl 2% (Rompun®, Bayer; 0.1 ml/kg), followed by intravenous propofol (3 mg/kg; Propofol 2%, Fresenius, Austria). After endotracheal intubation, anaesthesia was maintained with sevoflurane (2–3%; Sevofrane, Abbott, UK) in 100% oxygen.

Patients were positioned in lateral recumbency with the affected limb uppermost. Following routine aseptic preparation, intraoperative fluid therapy was provided using 0.9% NaCl (10 ml/kg/h, i.v.). All fractures were managed by open reduction.

A lateral surgical approach was performed, extending from the lateral humeral condyle to the distal extent of the ulnar fracture. The m. extensor digitorum lateralis and m. ulnaris lateralis were retracted to expose the fracture site. The cranially luxated radial head was identified and reduced using gentle traction and bone forceps. Reduction of the humeroulnar joint was achieved by controlled elbow extension, internal rotation of the carpus, and forelimb pronation. Because maintenance of ulnar stability during radial reduction was challenging, the ulna was first reduced and temporarily stabilised, followed by alignment of the radius relative to the ulna. Intraoperative assessment revealed annular ligament disruption in all cases, which was repaired using 2-0 polypropylene suture to ensure adequate mechanical support and restoration of radial head stability throughout the healing period.

Although the fixation construct followed the principles of a transarticular EF, pins were intentionally placed in the humerus and the radius/ulna, resulting in a temporary elbow-spanning configuration. This configuration was selected to maintain reduction of the radial head and protect the repaired annular ligament during the early healing phase and was intended as adjunctive stabilisation rather than definitive diaphyseal fracture fixation.

Depending on body size, four to six negative-profile threaded Schanz pins (1.5 mm diameter) were inserted

Fracture healing time was classified according to the criteria described by Kumar et al. (2012), with normal healing defined as fracture union within < 60 days without complications or deformity, and delayed healing defined as fracture union occurring after > 60 days. Malunion was defined as fracture union with angular deformity, whereas fixation failure was defined as the absence of fracture union. Overall limb function and clinical outcome were assessed subjectively based on previously published methodologies (Cook et al. 2010; Dinwiddie et al. 2021). Full function was defined as return to pre-trauma activity level without limitation; acceptable function as mild limitation in activity or duration with or without medical support; and unacceptable outcome as persistent functional impairment.

Complications were categorised as catastrophic, major, or minor according to established veterinary orthopaedic criteria. Following fixator removal, all patients were monitored for a minimum of six months. During this period, owners were contacted by telephone and requested to provide video recordings of ambulation, which were used as supportive information for clinical follow-up. Preoperative and postoperative radiographic and clinical evaluations were performed by the same surgical team.

Statistical analysis

Due to the limited sample size, statistical analysis was primarily descriptive. Continuous variables were expressed as mean \pm standard deviation, whereas categorical variables were presented as frequencies and percentages. Interobserver agreement for radiographic evaluation was assessed using the intraclass correlation coefficient (ICC). All statistical analyses were performed using IBM SPSS 22.1 Statistics (IBM Corp., Armonk, NY, USA). A value of $P < 0.05$ was considered significant. Inferential statistical comparisons were intentionally avoided to prevent overinterpretation of the findings.

Results

Radiographic findings and fracture healing process

Postoperative radiographic evaluation was performed at two-week intervals in orthogonal projections in all cases. The mean radiographic healing time was 40.5 ± 5.8 days. Normal fracture healing (< 60 days) was observed in eight cases, whereas delayed union (> 60 days) occurred in two cases. No radiographic evidence of synostosis, malunion, nonunion, or fixation failure was detected (Plates IX–XI, Figs 1–3). Postoperative radiographs demonstrated minor residual incongruities at the ulnar fracture site in some cases. Nevertheless, radiographic osseous union at the fracture line was confirmed in all patients prior to EF removal. Interobserver agreement for radiographic assessment was high, with an intraclass correlation coefficient (ICC) of 0.91, indicating excellent reliability ($P = 0.001$).

Clinical findings, amyotrophy, Campbell test and functional evaluation

Postoperative clinical evaluation revealed mild muscle atrophy of the affected limb in four cases (40%), characterised by asymmetrical reduction in muscle mass. No clinically evident amyotrophy was observed in the remaining six cases. The presence of amyotrophy was recorded alongside lameness scores, without further statistical comparison. Based on the Campbell test, elbow joint range of motion was within normal limits in two cases, showed mild limitation in flexion and extension in seven cases, and moderate limitation in one case. Functional outcome assessment demonstrated full functional recovery in six cases, acceptable function in three cases, and unacceptable outcome in one case. Lameness grading indicated that four cats had grade 0 lameness, three had grade 1, two had grade 2, and one had grade 3 lameness. The mean lameness score was 1.2 ± 0.9 .

Complications

Postoperative complications were observed in four cases. Pin tract infection occurred in three cats (30%) and was classified as a minor complication. These cases resolved with local pin-site care and did not require additional surgical intervention. One cat (10%) developed moderate soft tissue oedema accompanied by mild pin-site infection, which required additional medical treatment and was classified as a major complication. No catastrophic complications, such as permanent functional loss, euthanasia, or death, were observed.

Discussion

Monteggia fractures represent a complex orthopaedic injury pattern and are associated with a substantial risk of postoperative complications due to combined osseous and soft tissue involvement (Dukan et al. 2022; Schreiber et al. 2022; Anatolitou et al. 2024). The limited number of reported cases in veterinary medicine restricts the accumulation of robust clinical evidence and complicates the evaluation of optimal treatment strategies (Boero Baroncelli and Peirone 2009; Leclerc et al. 2014; Paladini 2025). Consequently, most available data are derived from isolated case reports or small retrospective series. No cases of cats treated with the external fixation technique for MFs fixation have been reported in the veterinary literature. In addition to providing up-to-date clinical information on MFs in cats, this study provides important data on the efficacy of the external fixation method in the treatment of MFs.

Unlike other long bone fractures, MF is divided into various types based on the direction of luxation of the radial head and localization of the fracture in the ulna. Although veterinary literature notes that Type I MF is most frequently encountered in animals and Type II MF is the least frequently reported, there are also studies presenting different findings (Irubetagoiena et al. 2011; Jimenez et al. 2021; Schreiber et al. 2022). In a recent study of nine cases (eight dogs, one cat), while Type I MF was found in all dogs, Type II MF was defined in the cat (Anatolitou et al. 2024). However, some studies have reported that Type IV MF is most commonly observed in cats (Irubetagoiena et al. 2011; Schreiber et al. 2022). There are more data on MFs in the human literature, and it has been reported that the most common type encountered in humans is Type I MF (Bor et al. 2015). In the present study, Type I MF was detected in all the cats examined. This variability between MF types reported in the veterinary literature may stem from the lack of a sufficient number of cases and data on the subject.

A variety of surgical techniques have been described for the management of MFs in small animals, including plate-and-screw fixation, intramedullary pinning with or without cerclage, transradioulnar positional screws, and annular ligament reconstruction using synthetic or suture-based methods (Boero Baroncelli and Peirone 2009; Vallone and Schulz 2011; Schreiber et al. 2022; Paladini 2025). While rigid fixation may provide stability, it can also restrict physiological forelimb rotation and necessitate implant removal, particularly in young or small patients (Irubetagoiena et al. 2011; Jimenez et al. 2021).

In the veterinary literature, traffic accidents, falling from height, bite injuries, and gunshot traumas have been reported in the aetiology of MFs (Leclerc et al. 2014). Among these causes, it has been frequently reported that the most common aetiological factor in dogs is traffic accidents, while in cats, it is falls from height (Irubetagoiena et al. 2011). Moreover, it has been observed that the incidence of MFs is higher in male animals than in females (Irubetagoiena et al. 2011; Schreiber et al. 2022; Anatolitou et al. 2024). Thoracic trauma, fractures occurring in other extremities, and accompanying radial head fractures are among the most frequently reported findings in cats and dogs with MFs (Schwarz and Schrader 1984; Schaeffer et al. 1999; Anatolitou et al. 2024). In the present study, MFs developed as a result of a fall from height in all cases, and the majority of the cases were male cats. The fact that cats live in a domestic environment increases the risk of falling from height; moreover, the hormonal structure of male cats causes a more aggressive behaviour profile, which may explain this occurrence (Gülaydın and Alkan 2024). In addition to these findings, only one cat in the study was found to have carpal dislocation of the contralateral forelimb with MF, and this case also experienced successful recovery.

One of the most important issues related to MFs is the complications encountered during the postoperative period (Anatolitou et al. 2024). Although many authors have reported

favourable results with surgical techniques applied in the treatment of MFs, they also emphasize that various complications are encountered (Leclerc et al. 2014; Jimenez et al. 2021; Schreiber et al. 2022). These observed complications may develop due to both the fact that MF is a complex orthopaedic problem and the characteristics of the fixation technique applied (Gülaydın and Alkan 2024). Fixation materials such as plates, screws, pins, and tension bands are used alone or in combination in the treatment of MF (Boero Baroncelli and Peirone 2009; Vallone and Schulz 2011; Schreiber et al. 2022). However, various complications, such as synostosis, joint relaxations, ankylosis, chronic lameness, instability, osteoarthritis, and osteomyelitis, have been reported (Schaeffer et al. 1999; Irubetagoyena et al. 2011; Jimenez et al. 2021; Schreiber et al. 2022; Anatolitou et al. 2024). In both human and veterinary medicine literature, similar postoperative complications have been reported in studies in which EF was applied to treat MF (Yuan et al. 2019; Jimenez et al. 2021). For example, complications such as dermatitis around the incision line, ulceration at pin insertion sites, and pitting oedema were reported following EF application in a langur, a primate species (Jimenez et al. 2021). In the present study, the most common complication in cats was pin tract infection. However, these infections were successfully treated with timely intervention, and progression was prevented.

The main contribution of this study is in providing original and valuable data to the lack of information in this field, given that external fixation, which is a current treatment method successfully applied in human medicine, has been reported in a limited number of cases of MF in the veterinary literature. Although favourable results have been reported in MF cases in previous studies, ulnar union was delayed in closed reduction and bandage applications (Schwarz and Schrader 1984). However, the use of plates, cerclage wires, and intramedullary pins in the reduction of ulnar fractures has also been reported (Irubetagoyena et al. 2011; Leclerc et al. 2014; Schreiber et al. 2022). Among these methods, intramedullary pin applications provide advantages such as low cost and easy applicability, while providing less rigidity than plate and screw applications (Anatolitou et al. 2024). However, one study reported that plate application may cause irritation of the triceps tendon (Irubetagoyena et al. 2011). It has also been emphasized that screws placed in the radius and ulna in screw applications used for radial fixation may adversely affect bone development and limit supination and pronation movements of the extremities, especially in mobile animals such as cats (Irubetagoyena et al. 2011; Leclerc et al. 2014; Koch 2017; Jimenez et al. 2021). Hence, screws placed for fixation in such cases should be removed with a second surgical intervention after four weeks (Koch 2017; Anatolitou et al. 2024).

Although no method is perfect for fracture treatment, EF applications used in the treatment of MFs also have some specific disadvantages. These disadvantages include the need for the surgeon to be experienced in this technique and cases of iatrogenic neurological damage reported in some studies (Lu et al. 2013; Dukan et al. 2022). Yet, some of the risks reported in the veterinary and human literature in the treatment of MFs were not observed either in the present study or in similar studies in which EF was applied (Irubetagoyena et al. 2011; Bor et al. 2015; Jimenez et al. 2021). For instance, one study reported that temporary fixation with an EF in the treatment of Type I MF in children facilitated plate fixation by allowing flexible adjustments in osteotomy angle and length, and no radial head luxation or subluxation was observed in any patient because of the advantages offered by this method (Wang et al. 2019). In case studies in the veterinary literature, Jimenez et al. (2021) reported that a limitation in range of motion developed after hinged Type 1a linear transarticular EF with a radioulnar screw in a Type II MF case in the primate langur, but this limitation improved with physical therapy following the removal of the EF and screw. Similarly, another study

reported that mild but persistent chronic lameness developed in a dog after a combination of plate and hinged EF (Boero Baroncelli and Peirone 2009).

In the present study, an epoxy resin-supported transarticular EF with temporary elbow-spanning stabilisation was used as an adjunctive technique to maintain reduction of the radial head and protect annular ligament repair. Although postoperative complications were observed, most were minor and resolved with conservative management, which is consistent with complication profiles reported for external fixation systems in both veterinary and human orthopaedics (Yuan et al. 2019; Jimenez et al. 2021).

The status of the annular ligament represents a critical factor in the stability of the radiocapitellar joint (Schreiber et al. 2022). Consistent with previous recommendations, annular ligament repair was performed in all cases using polypropylene suture material, and postoperative joint stability assessed by the Campbell test was generally acceptable (Aydın and Yayla 2018; Schreiber et al. 2022). However, objective assessment of long-term joint congruity and degenerative changes was beyond the scope of this study.

Intra-articular ulnar fractures pose an additional challenge in the management of Monteggia injuries, as joint incongruity may predispose to osteoarthritis even after fracture union (Macias and McKee 2003; Vallone and Schulz 2011). In contrast, Sanchez et al. (2017) reported that the healing process was not adversely affected despite intra-articular ulnar fractures in a young cat (Sanchez et al. 2017). Together with this, the fact that cats tolerate orthopaedic problems affecting their extremities better than dogs, and that the prognosis of the healing process is generally more favourable in young animals, may have contributed to the favourable clinical outcomes observed in the present study (Bordelon et al. 2005; Risselada et al. 2005). In the present series, cases with intra-articular involvement were included; however, due to the retrospective design, limited sample size, and absence of long-term objective outcome measures, conclusions regarding articular fracture management should be interpreted with caution.

The primary limitations of this study include its retrospective case series design, small sample size, lack of a comparative control group, and reliance on subjective clinical outcome measures. Consequently, the findings should be viewed as descriptive and hypothesis-generating rather than definitive evidence of treatment superiority.

In conclusion, the findings of this retrospective case series suggest that the use of an epoxy resin-supported Type Ia transarticular EF with temporary elbow-spanning stabilisation may represent a viable treatment option for selected feline Type I MF. However, given the descriptive nature of the study, limited sample size, and absence of long-term objective outcome assessment, careful case selection and cautious interpretation of clinical results are warranted. Further prospective and comparative studies are required to more clearly define the role of this technique in feline MF management.

Conflict of interest

The authors declare that they have no known competing financial interests or personal relationships that could have appeared to influence the work reported in this paper.

References

- Anatolitou A, Krystalli AA, Sideri KI, Markou M, Kazakos G, Prassinou NN 2024: A retrospective study of Monteggia fractures in 8 dogs and 1 cat. *Top Companion Anim Med* **61**: 100889
- Aydın U, Yayla S 2018: Type I Monteggia fracture in a kitten; a review on diagnostic and therapeutic methods. *Dicle Univ Vet Fak Derg* **11**: 115-117
- Boero Baroncelli A, Peirone B 2009: Trattamento di una frattura di Monteggia in un cane (Treatment of a Monteggia fracture in a dog). *Veterinaria* **23**: 47-51
- Bordelon JT, Reaugh HF, Rochat MC 2005: Traumatic luxations of the appendicular skeleton. *Vet Clin North Am Small Anim Pract* **35**: 1169-1194
- Bor N, Rubin G, Rozen N, Herzenberg JE 2015: Chronic anterior Monteggia lesions in children: report of 4 cases treated with closed reduction by ulnar osteotomy and external fixation. *J Pediatr Orthop* **35**: 7-10

- Cook JL, Evans R, Conzemius MG, Lascelles BD, McIlwraith CW, Pozzi A, Clegg P, Innes J, Schulz K, Houlton J, Fortier L, Cross AR, Hayashi K, Kapatkin A, Brown DC, Stewart A 2010: Proposed definitions and criteria for reporting time frame, outcome, and complications for clinical orthopedic studies in veterinary medicine. *Vet Surg* **39**: 905-908
- Dinwiddie EV, Rendahl A, Veytsman S, Ragetly G, Lynch AC, Minitzer BB, Ben-Amotz R 2021: Evaluation of post-operative complications, outcome, and long-term owner satisfaction of elbow arthrodesis in 22 dogs. *PLoS One* **16**: e0255388
- Dukan R, Le Hanneur M, Pannier S, Fitoussi F 2022: Use of an external fixator during one-step surgical management of missed chronic Monteggia injuries. *Orthop Traumatol Surg Res* **108**: 102963
- Gülaydın A, Alkan İ 2024: Evaluation of distal femur fractures in cats by hybrid external fixator. *Ankara Univ Vet Fak Derg* **71**: 89-100
- Irubetagoiena I, Lopez T, Autefage A 2011: Type IV Monteggia fracture in a cat. *Vet Comp Orthop Traumatol* **24**: 483486
- Jimenez IA, Spector DI, Chaney SB, Moore R, Paré JA 2021: Surgical stabilization of traumatic elbow joint luxation and proximal ulnar fracture in a silvery langur (*Trachypithecus cristatus*). *J Am Vet Med Assoc* **259**: 1466-1470
- Koch DA 2017: Einfache Methode zur Stabilisierung von Monteggia Frakturen bei der Katze (Simple repair of Monteggia fractures in the cat). *Schweiz Arch Tierheilkd* **159**: 601-604
- Kumar P, Aithal HP, Kinjavdekar P, Amarpal, Pawde AM, Pratap K, Tyagi SK, Sinha DK 2012: Epoxy-pin external skeletal fixation for treatment of open fractures or dislocations in 36 dogs. *Indian J Vet Surg* **33**: 128-132
- Leclerc A, Greunz EM, Daude-Lagrave A 2014: Surgical treatment of a type III Monteggia fracture in a ring-tailed lemur (*Lemur catta*). *Rev Med Vet* **165**: 313-317
- Lu X, Wang YK, Zhang J, Zhu Z, Guo Y, Lu M 2013: Management of missed Monteggia fractures with ulnar osteotomy, open reduction, and dual-socket external fixation. *J Pediatr Orthop* **33**: 398-402
- Macias C, McKee M 2003: Articular and periarticular fractures in the dog and cat. *In Pract* **25**: 446-465
- Özak A, Yardımcı C, Nısbet HÖ, Şirin YS 2009: Treatment of long bone fractures with acrylic external fixation in dogs and cats: retrospective study in 30 cases (2006–2008). *Kafkas Univ Vet Fak Derg* **15**: 615-622
- Paladini A 2025: Surgical treatment of a Monteggia fracture in a cat. *Tierarztl Prax Ausg K Kleintiere Heimtiere* **53**: 111-116
- Risselada M, Kramer M, de Rooster H, Taeymans O, Verleyen P, van Bree H 2005: Ultrasonographic and radiographic assessment of uncomplicated secondary fracture healing of long bones in dogs and cats. *Vet Surg* **34**: 99-107
- Sanchez AF, Calvo I, Farrell M 2017: Articular type II Monteggia fracture with concurrent humeroulnar luxation in a Bengal cat. *Vet Rec Case Rep* **7**: e000697
- Schaeffer IGF, Wolvekamp P, Meij BP, Theijse LFH, Hazewinkel HAW 1999: Traumatic luxation of the elbow in 31 dogs. *Vet Comp Orthop Traumatol* **12**: 33-39
- Schreiber K, Rousseau T, Gauthier O 2022: Type II Monteggia lesion with complete elbow dislocation in a cat. *VCOT Open* **5**: e30-e35
- Schwarz PD, Schrader SC 1984: Ulnar fracture and dislocation of the proximal radial epiphysis (Monteggia lesion) in the dog and cat: a review of 28 cases. *J Am Vet Med Assoc* **185**: 190-194
- Vallone L, Schulz K 2011: Repair of Monteggia fractures using an Arthrex Tightrope system and ulnar plating. *Vet Surg* **40**: 734-737
- Wang Q, Du MM, Pei XJ, Luo JZ, Li YZ, Liu YC, Wang X, Cao JC, Han JH 2019: External fixator-assisted ulnar osteotomy: a novel technique to treat missed Monteggia fracture in children. *Orthop Surg* **11**: 102-108
- Yuan Z, Xu H, Li Y, Li J, Liu Y, Canavese F 2020: Functional and radiological outcome in patients with acute Monteggia fracture treated surgically: a comparison between closed reduction and external fixation versus closed reduction and elastic stable intramedullary nailing. *J Pediatr Orthop B* **29**: 438-444
- Yuan Z, Xu HW, Liu YZ, Li YQ, Li JC, Canavese F 2019: The use of external fixation for the management of acute and chronic Monteggia fractures in children. *J Child Orthop* **13**: 551-559

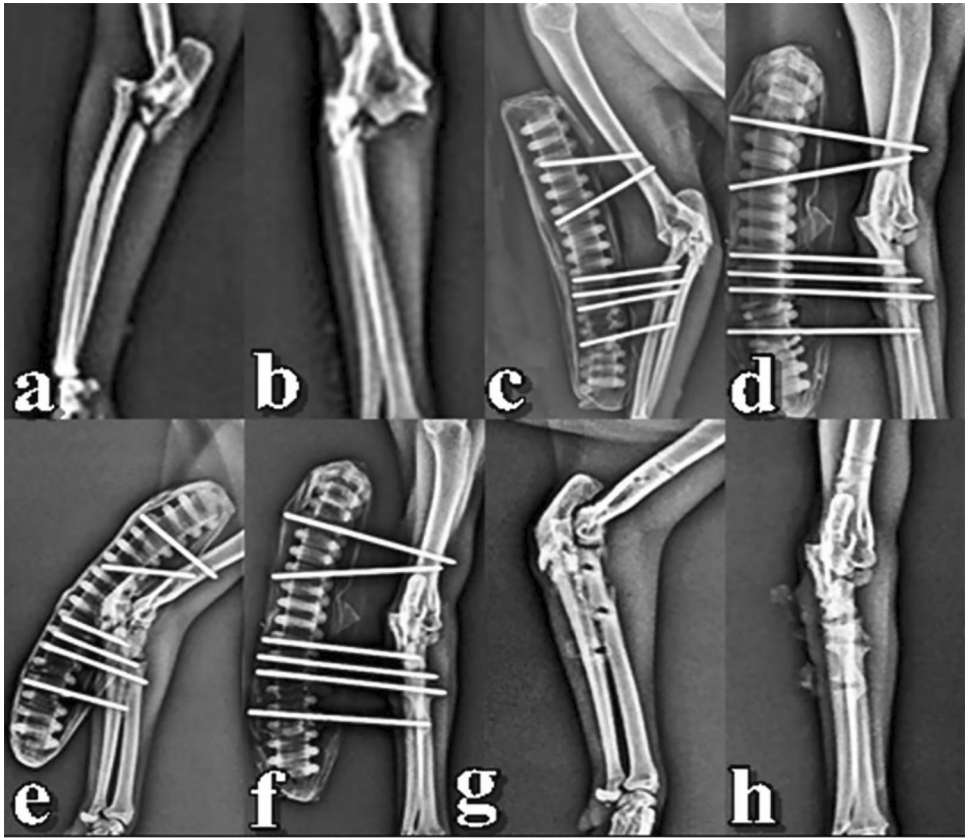


Fig. 1. Radiography examination of Case 6 (extra-articular ulna fracture): (a-b) preoperative orthogonal radiographic images; (c-d) radiographic views obtained at postoperative week 2; (e-f) radiographic images at postoperative week 6, before EF removal; (g-h) early postoperative radiographic images after EF removal.

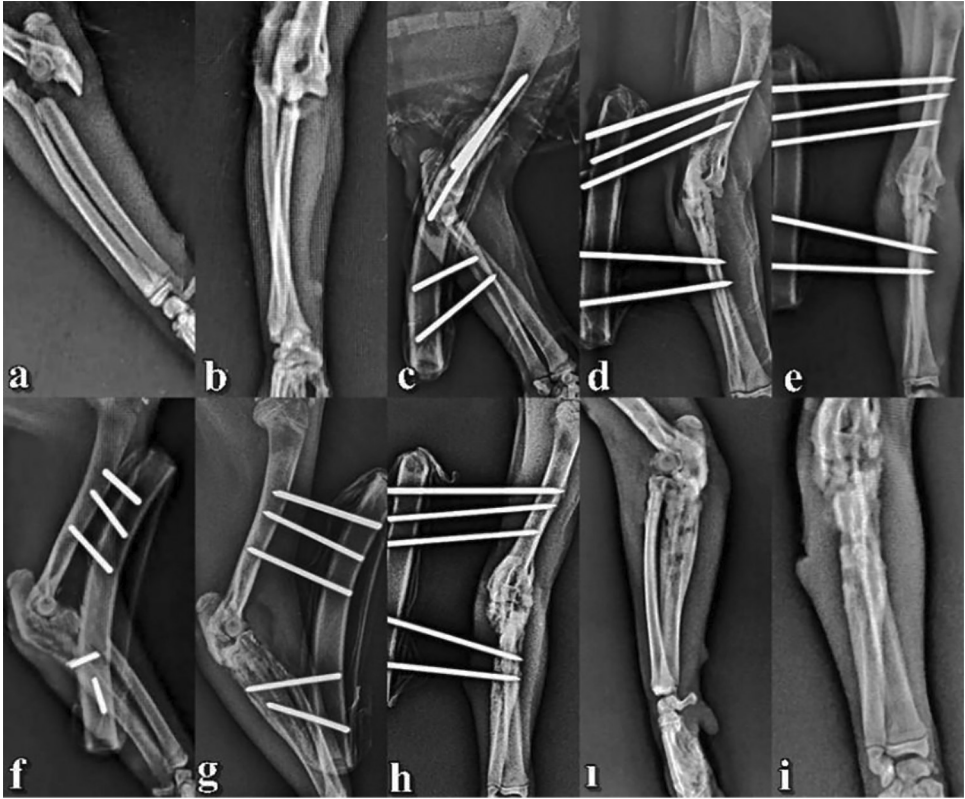


Fig. 2. Radiography examination of Case 2 (intra-articular ulna fracture): (a-b) preoperative orthogonal radiographic images; (c-d) radiographic images at postoperative day 0; (e-f) radiographic images at postoperative week 2; (g-h) radiographic images at postoperative week 4, before external fixator (EF) removal; (i-i) early postoperative radiographic images after EF removal.

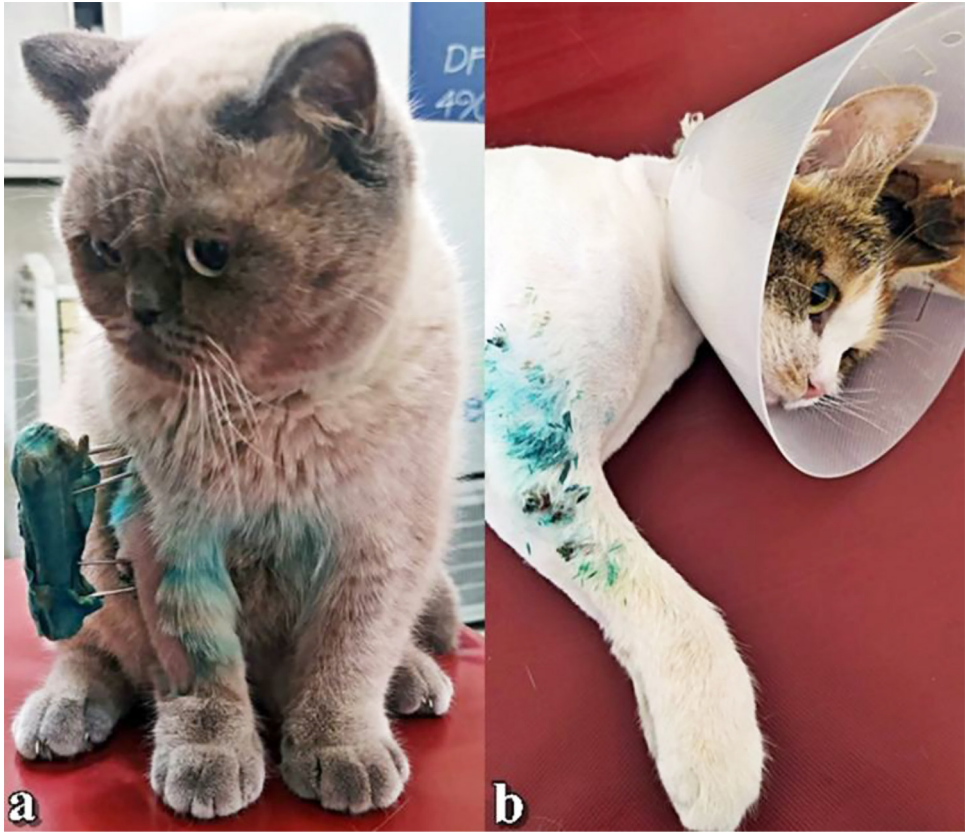

Fig. 3. Clinical images: (a) Case 2 at postoperative week 4 before external fixator (EF) removal; (b) Case 6 at postoperative week 6 after EF removal under sedation.